

EMAIL REQUEST

**ARIEL**



90476466

**B COPY**

R.D.  
09-Mar-05072

P.D.  
09-Mar-05081

Customer Code No.  
20-0475

Shelfmark  
5052.070000

134

JOURNAL OF RHEUMATOLOGY  
2004 VOL 31 PP (617-619)  
WHALE M.

*Handwritten signature*

OS FLOOR 4-3  
JOURNAL OF RHEUMATOLOGY.  
SEE ALSO SERIAL RECORDS RSM AND .  
D1 S1 (P) GU 89 -E(5) 2004

20-0475

*Handwritten 'A43'*



90476466

for RMS  
use only

International Loan, Return Airmail within 4  
weeks of date of receipt unless recalled earlier.

Request Ref. No.  
GZGZ 00067882 FXBK99

If no other library indicated please return loan to:-  
The British Library Document Supply Centre, Boston Spa,  
Wetherby, West Yorkshire, United Kingdom, LS23 7BQ

\*\*\*\*\*  
\* PLEASE SEND BY ARIEL \*  
\* EMAIL: \*  
\* MXKLB.MASCHINENUSER@BAYERBBS.COM --- \*  
\* \*\*\*\*\*047 \*  
**ARIEL**

C

C

047



# DELIVERING THE WORLD'S KNOWLEDGE

This document has been supplied by the British Library  
[www.bl.uk](http://www.bl.uk)

The contents of the attached document are copyright works. Unless you have the permission of the copyright owner, the Copyright Licensing Agency Ltd or another authorised licensing body, you may not copy, store in any electronic medium or otherwise reproduce or resell any of the content, even for internal purposes, except as may be allowed by law.

If the request form above has the word 'Copyright' written in large text, it was supplied under our Copyright Fee Paid service. You are therefore agreeing to the terms of supply for our Copyright Fee Paid service, available at [www.bl.uk/services/document/edd.html](http://www.bl.uk/services/document/edd.html)

If the request form above does not have the word 'Copyright' written in large text, it was supplied through our Library Privilege service. You are therefore agreeing to the terms of supply for our Library Privilege service, available at [www.bl.uk/services/document/lps.html](http://www.bl.uk/services/document/lps.html)

# Unusual Differential Diagnosis of a Swollen Toe

MATTHIAS WAHLE and CHRISTOPH G.O. BAERWALD

**ABSTRACT.** We describe a 49-year-old woman presenting with a swollen toe. After a surgeon recommended amputation, further investigations resulted in the diagnosis of lymphocytoma cutis as a manifestation of Lyme disease at an unusual site. Although the distribution of cutaneous manifestations in Lyme disease varies geographically, rheumatologists should be familiar with the diagnosis and treatment of Lyme disease in all its forms. (J Rheumatol 2004;31:617-9)

*Key Indexing Terms:*  
LYME DISEASE

PSEUDOLYMPHOMA

DIAGNOSIS

We describe a 49-year-old woman presenting with a swollen toe. Investigations resulted in the diagnosis of lymphocytoma cutis as a manifestation of Lyme disease. Although the distribution of cutaneous manifestations in Lyme disease varies, rheumatologists should be familiar with the diagnosis and treatment of Lyme disease in all its forms.

## CASE REPORT

A 49-year-old female patient was referred to our outpatient clinic with a several-week history of pain and red to violaceous swelling of the second toe of the left foot. She had previously consulted a surgeon, where a first biopsy led to the diagnosis of sarcoidosis and therapy with oral corticosteroids was initiated. Since this therapy did not resolve the problem, the surgeon recommended amputation of that toe. The patient was then referred to our rheumatology department for a second opinion whether a systemic disease was underlying that process. At presentation the symptoms had been slowly increasing for 6 months (Figure 1). Examination showed a swelling of the dermis and subcutaneous tissue, while palpation of the interphalangeal joints did not reveal any tenderness or effusion. She was in good clinical condition, afebrile, and had no other physical abnormality. In particular, no swollen or tender lymph nodes were detectable.

She had no history of travel and was taking no medication. A thoracic radiograph and an ultrasonographic study of the abdomen and pelvis revealed no abnormalities. Laboratory studies showed normal values for white blood cell count, liver function tests, angiotensin-converting enzyme, and C-reactive protein. Another biopsy was taken from the toe and a test on *Borrelia burgdorferi* antibodies was performed, since she lived in an area endemic for Lyme disease. Histological examination revealed dense cellular infiltration predominately composed of lymphocytes and plasma cells in the dermis and subcutaneous tissue, with formation of germinal centers compatible with lymphocytoma cutis (Figure 2). Together with the positive serologic tests for *Borrelia* antibodies [ELISA: IgM negative, IgG 257 U/ml (cutoff < 44 U/ml); Western blot IgG: 25, 30, 34, 37, 39, 41, 48, 60, and 70 kDa positive] the diagnosis of Lyme disease was made. Treatment with ceftriaxone (2 g intravenously per day) for 21 days led to complete remission of the cutaneous findings. She was still well 2 years after completing the course of antibiotics (Figure 3).

*From the Department of Medicine, Clinic and Polyclinic IV, University Hospital, University of Leipzig, Leipzig, Germany.*

*M. Wahle, MD, Postdoctoral Fellow; C.G.O. Baerwald, MD, Professor of Medicine.*

*Address reprint requests to Dr. M. Wahle, Department of Medicine, Clinic and Polyclinic IV, University Hospital, Liebigstrasse 22, 04103 Leipzig, Germany. E-mail: wahm@medizin.uni-leipzig.de*

*Submitted June 9, 2003; revision accepted September 29, 2003.*

*Differential diagnosis.* With no hint of a systemic disease on clinical and laboratory examination a local process was considered to be the culprit. Classic variants of cutaneous borreliosis are erythema migrans, lymphocytoma cutis (LC or lymphadenosis cutis benigna), and acrodermatitis chronica atrophicans. Usually LC occurs as a purplish nodule at the ear lobe, the nose, the forehead, or at the nipple. We describe this cutaneous manifestation at an unusual site, diagnosed by biopsy and a positive serologic titer. Recently, polymerase chain reaction (PCR) technology has been applied in diagnosing *Borrelia* infection in various tissues, and it is now the mainstay in diagnosing difficult cases. Differential diagnoses include various diseases with cutaneous infiltrates of mainly mononuclear cells. In particular, specific infiltrates of B cell chronic lymphocytic lymphoma (B-CLL) with a dense, monomorphous infiltrate of small, hyperchromatic lymphocytes within the entire dermis and partly nodular aggregates in the subcutis should be taken into account. In cutaneous T cell lymphoma (CTCL) T cells with hyperchromatic irregularly-shaped nuclei are predominant. However, in neither B-CLL nor CTCL are germinal centers observed<sup>1,2</sup>. Benign hyperplastic lymphoid infiltrates (pseudolymphoma) with B cell-predominant or T cell-predominant infiltrates simulate lymphoma clinically and can be distinguished from LC histologically<sup>3</sup>. Similarly, LC can mimic insect bite reactions, which can be diagnosed using recently proposed indications for histopathologic diagnosis<sup>4</sup>. With respect to the initial diagnosis of sarcoidosis in our patient, the hallmark for this diagnosis was missing, i.e., noncaseating granulomas on skin biopsy<sup>5</sup>.

## DISCUSSION

Since Lyme borreliosis has been recognized as a clinical entity<sup>6</sup> the disease has been described in the temperate zone of the northern hemisphere. The infection is caused by *Borrelia burgdorferi* sensu lato, a gram-negative spirochete transmitted by the usually asymptomatic bite of certain ticks of the genus *Ixodes*<sup>7</sup>. The clinical manifestations of Lyme disease are frequently categorized as early localized disease (erythema migrans), followed within weeks by disseminated infection (e.g., Bell's palsy, atrioventricular block, arthralgia/arthritis) and subsequently, within months, by late or chronic (persistent) infection (e.g., arthritis, acrodermatitis atrophicans)<sup>8</sup>.

To date 3 *Borrelia* species are pathogenic for humans exhibiting different tissue tropism. Distribution of pathogenic *Borrelia* species is different in North America (*B. burgdorferi* sensu stricto) and Europe (*B. burgdorferi* sensu stricto, *B. garinii*, *B. afzelii*), which is considered to account

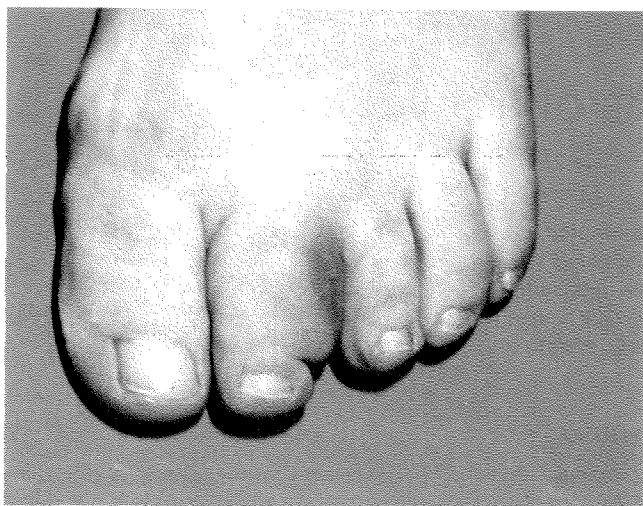

Figure 1. Painful swelling of the second toe of the left foot in a 49-year-old woman.

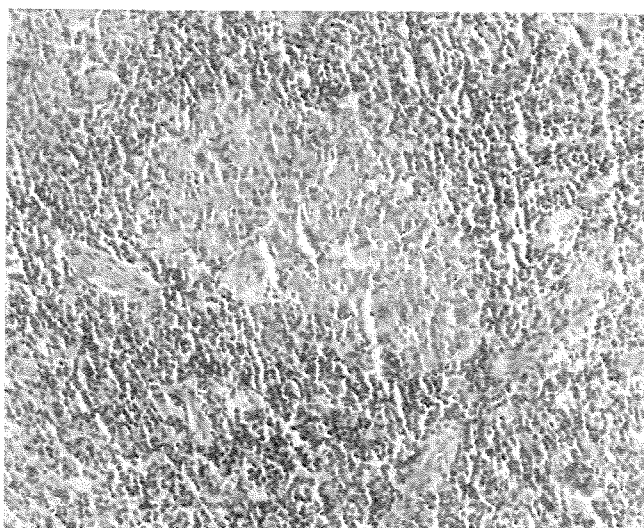


Figure 2. Histological examination shows dense cellular infiltration composed of lymphocytes and plasma cells in the dermis and subcutaneous tissue, with formation of germinal centers compatible with lymphocytoma cutis.

for the various clinical manifestations of Lyme disease. In the Leipzig area about a quarter of investigated ticks were positive for borrelial DNA, with 12% of the positive ticks being infected with 2 or more subspecies. *B. afzelii* (38%) is the most frequent subspecies isolated from ticks, followed by *B. garinii* (31%) and *B. burgdorferi sensu stricto* (12%)<sup>9</sup>.

Cutaneous manifestations of disseminated as well as late infection are well documented in European patients with Lyme disease, but are rarely seen in the United States<sup>10</sup>. As noted, LC in the early disease state is sometimes difficult to differentiate from primary cutaneous B cell lymphoma. As erythema migrans, LC usually is a self-limiting disease. However, long-standing course as in our patient as well as

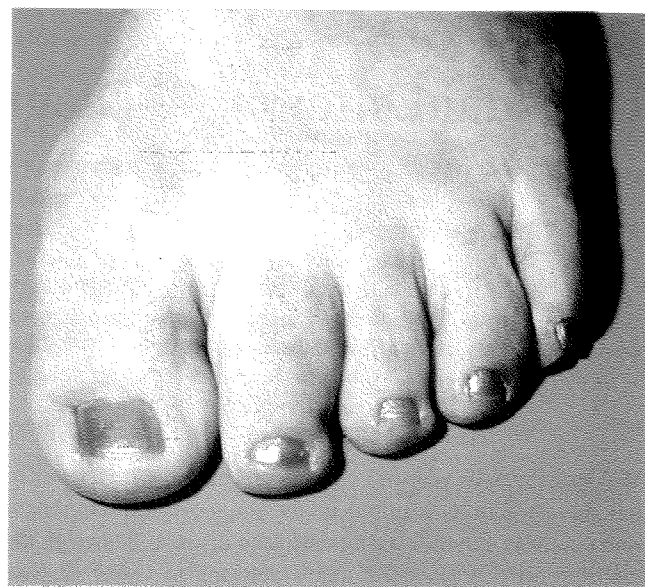


Figure 3. Treatment with ceftriaxone for 21 days led to remission of cutaneous findings.

recurrent disease has been observed. Further, true *B. burgdorferi*-associated B cell lymphomas have been described, underlining the potentially chronic course of LC. With detection of *Borrelia* DNA in LC using a PCR technique, a recent report described borrelial species in suspected or confirmed cases of primary cutaneous B cell lymphoma. This led to the suggestion of antibiotic therapy as a first-line treatment of primary cutaneous B cell lymphoma in regions with endemic *B. burgdorferi* infection<sup>11</sup>.

Considering this evidence, the diagnosis of Lyme disease should rest on a careful history and objective clinical findings, supported by appropriate laboratory tests. Hence, it pays to perform a second diagnostic procedure and to keep in mind that in rare cases lymphocytoma cutis can occur at unusual sites without previous manifestation of erythema migrans.

#### REFERENCES

1. Cerroni L, Hofler G, Back B, Wolf P, Maier G, Kerl H. Specific cutaneous infiltrates of B-cell chronic lymphocytic leukemia (B-CLL) at sites typical for *Borrelia burgdorferi* infection. *J Cutan Pathol* 2002;29:142-7.
2. Kazakov DV, Kempf W, Michaelis S, et al. T-zone lymphoma with cutaneous involvement: a case report and review of the literature. *Br J Dermatol* 2002;146:1096-100.
3. Gilliam AC, Wood GS. Cutaneous lymphoid hyperplasias. *Semin Cutan Med Surg* 2000;19:133-41.
4. Zelger B. Ten clues to the histopathologic diagnosis of infectious skin diseases. *Pathologe* 2002;23:38-45.
5. Young RJ III, Gilson RT, Yanase D, Elston DM. Cutaneous sarcoidosis. *Int J Dermatol* 2001;40:249-53.
6. Steere AC, Malawista SE, Snyderman DR, et al. Lyme arthritis: an epidemic of oligoarticular arthritis in children and adults in three Connecticut communities. *Arthritis Rheum* 1977;20:7-17.

7. Burgdorfer W, Barbour AG, Hayes SF, Benach JL, Grunwaldt E, Davis JP. Lyme disease — a tick-borne spirochetosis? *Science* 1982;216:1317-9.
8. Nadelman RB, Wormser GP. Lyme borreliosis. *Lancet* 1998;352:557-65.
9. Klapper BM. Untersuchungen zur Epidemiologie der Borreliose im Freistaat Sachsen — Verbreitung von *Borrelia burgdorferi* in Zecken und Antikörperbestimmung in Humanseren. [Epidemiology of borreliosis in Saxony — distribution of *Borrelia burgdorferi* in ticks and antibodies in human sera] [dissertation]. Leipzig: University of Leipzig; 1999.
10. Steere AC. Lyme disease. *N Engl J Med* 2001;345:115-25.
11. Grange F, Wechsler J, Guillaume JC, et al. *Borrelia burgdorferi*-associated lymphocytoma cutis simulating a primary cutaneous large B-cell lymphoma. *J Am Acad Dermatol* 2002;47:530-4.